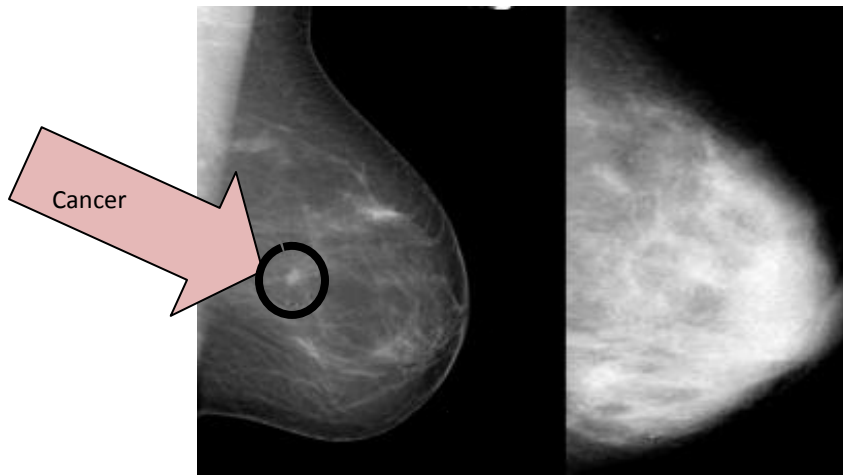


What is Dense Breast Tissue?

Dense breast tissue is comprised of less fat and more connective/fibrous and glandular tissue. On a mammogram, dense tissue appears white and cancerous tumors appear white making it nearly impossible to "see" the tumor.



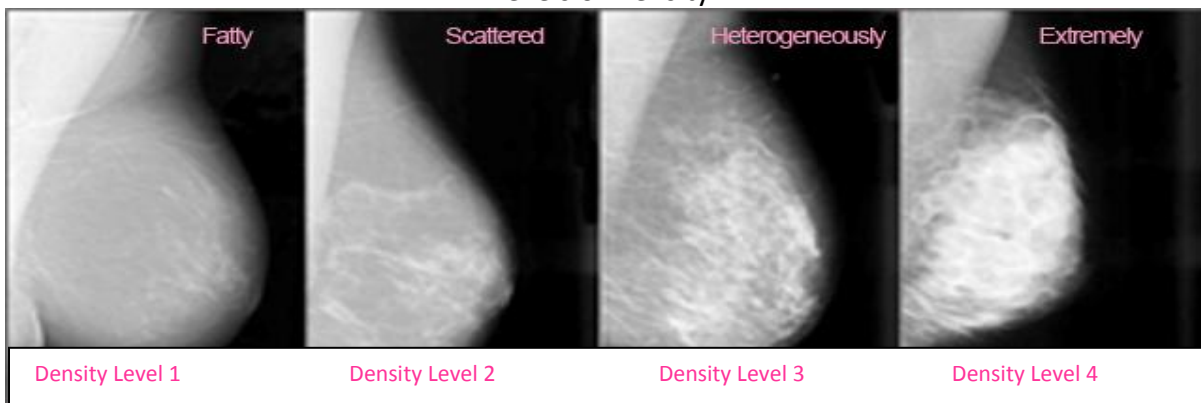
Fatty Breast

Dense Breast

On the left is a mammogram of a fatty breast. Since fat is radiolucent it produces a dark background which makes the small, white tumor in the center of the breast relatively easy to see. The mammogram on the right shows a very dense breast. It too has a cancer in roughly the same location but I challenge you to find it. (Photo from a lecture courtesy of Dr. Ellen Warner, Sunnybrook & Women's College Health Sciences, Toronto, Canada)

Dense Breast Tissue

Levels of Density



Are
You
DENSE?
exposing the best-kept secret