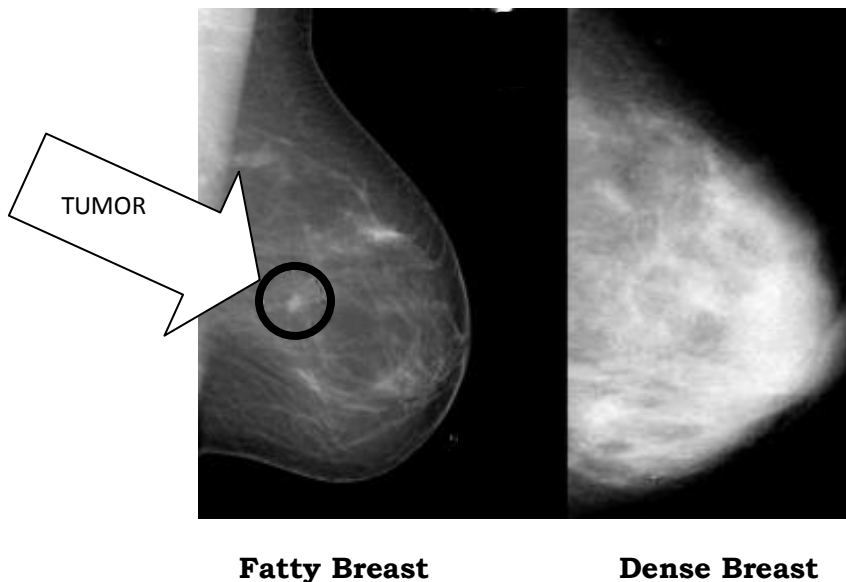


What is Dense Breast Tissue?

Dense breast tissue is comprised of less fat and more glandular and connective tissue. A radiologist categorizes a woman's breast density based on viewing her mammogram. The density category ranges in a scale from 1 to 4 (fatty to extremely dense). On a mammogram, dense tissue appears white and cancerous tumors appear white making it nearly impossible to "see" the tumor.



On the left is a mammogram of a fatty breast. Since fat is radiolucent it produces a dark background which makes the small, white tumor in the center of the breast relatively easy to see. The mammogram on the right shows a very dense breast. It too has a cancer in roughly the same location but I challenge you to find it.

Photo from a lecture by Dr. Ellen Warner of Sunnybrook & Women's College Health Sciences, Toronto, Canada.

Are
ou
DENSE?
exposing the best-kept secret®
www.areyoudense.org

www.areyoudense.org