



MBI casts wider net for improved breast cancer diagnosis




MBI could help breast centers caught in economic squeeze



Radiation dose in women's imaging: Are we scared yet?



New imaging tools address challenges of dense breast tissue



When to use advanced breast imaging: A tale of two centers

## Welcome to Advances in Molecular Breast Imaging, a new AuntMinnie.com special report on MBI, an exciting new technology in breast imaging.

Radiologists are investigating MBI as an alternative to other adjunctive breast imaging technologies, such as breast MRI and ultrasound, in working up women with suspicious lesions found on mammography. In the future, MBI could even develop a role as a screening modality for certain segments of the population.

In these pages you'll find a comprehensive review of MBI, touching on everything from its viability in today's cost-conscious breast imaging practice to how it fits into an environment increasingly worried about radiation dose. You'll also learn about how specialized breast imaging practices plan to integrate MBI into their operations, and whether MBI could offer a solution to one of the most vexing problems in breast imaging -- dealing with dense breast tissue.

We hope you find this report informative and useful as you strive to provide the best available care to patients.

Brian Casey, Editor in Chief, AuntMinnie.com

advances in...

# MBI

MOLECULAR BREAST IMAGING

AN AUNTMINNIE.COM SPECIAL REPORT



SPONSORED BY:



## MBI casts wider net for improved breast cancer diagnosis

The woman participating in a proof-of-concept clinical trial of molecular breast imaging (MBI) for screening use was at risk of breast cancer, despite religiously undergoing annual x-ray mammography in the five years since her 40th birthday.

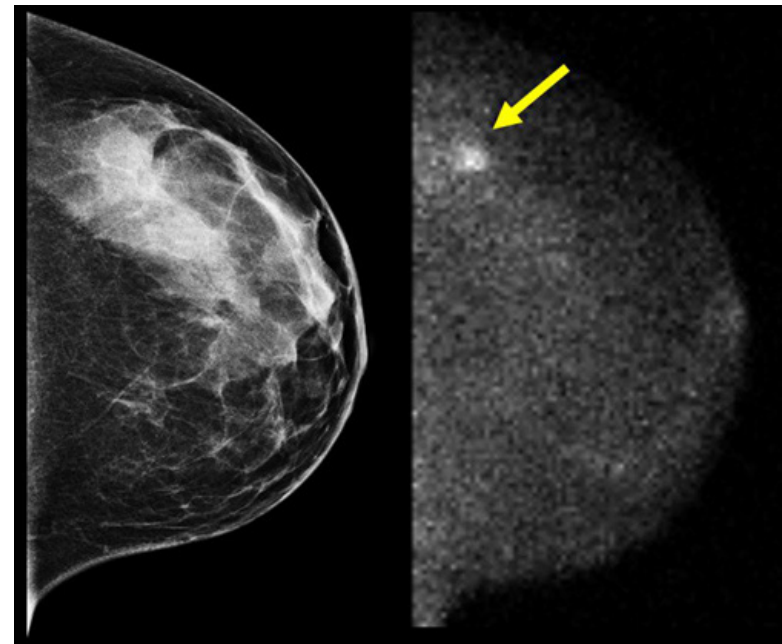
In those years, nothing suspicious had been detected in the shadowy presentation of her unusually dense breasts, and, again, nothing appeared on mammography images acquired in the Mayo Clinic trial. But when she was examined with molecular breast imaging, an intensely bright focus, indicative of a large lobular cancer, appeared on the images.

MBI uncovered five other cancers that escaped detection with mammography in the trial, but the memory of this patient persisted for Carrie Hruska, PhD, an associate consultant in medical physics at the Mayo Clinic in Rochester, MN, as she presented preliminary results from the trial at the American Society of Breast Disease (ASBD) meeting in New York City in April 2010.

"I can safely say that we saved her life by screening with MBI," Hruska said.

### A new arrival

MBI is the latest arrival in a new generation of functional breast imaging technology designed to overcome the limitations of anatomic breast imaging.



A 45-year-old woman with elevated risk for breast cancer due to breast density underwent digital screening mammogram (left) and screening MBI (right) as part of a clinical trial. A biopsy from the area of suspicious technetium-99m (Tc-99m) sestamibi uptake (arrow) indicated the presence of a large lobular carcinoma. All images courtesy of Carrie Hruska, PhD.

Though mortality rates have declined, breast cancer remains a nefarious disease. In the U.S. alone, it killed more than four women every hour of every day in 2006, the last year for which complete data are available.

It is no secret that cases escape notice through holes in the current diagnostic armamentarium of screening

x-ray mammography, diagnostic mammography and ultrasound, and breast MRI. Practitioners and patient advocates complain that too many interval cancers are missed and too many benign or non-life-threatening masses are biopsied and treated.

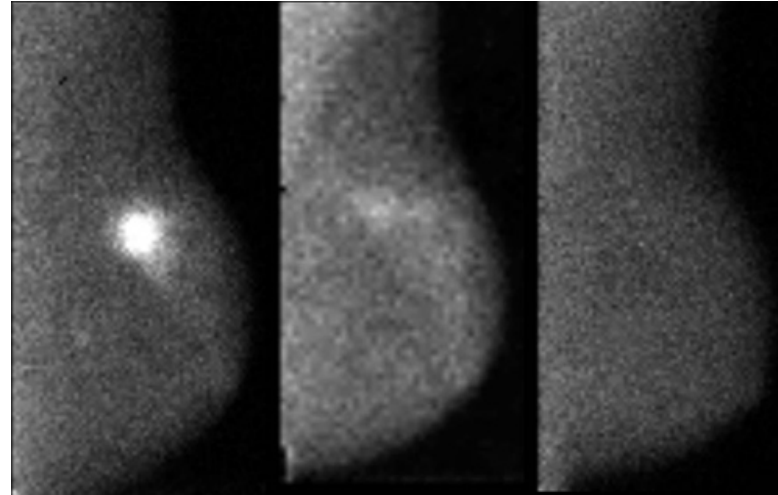
MBI may help fill the breach. Early work took place at Mayo, which has licensed its technology to Gamma Medica (GM) of Northridge, CA, for commercialization. Multimodality vendor GE Healthcare of Chalfont St. Giles, U.K., announced in June that it, too, is investigating MBI.

MBI shares family ties with other functional approaches to breast imaging, including breast-specific gamma imaging (BSGI) and positron emission mammography (PEM). All three capitalize on diagnostic nuclear imaging methods.

MBI and BSGI employ gamma cameras specifically designed for breast examination using technetium-99m (Tc-99m) sestamibi, the preferred radiopharmaceutical probe for tumor localization and imaging. Tc-99m is the workhorse radioisotope for such single-photon imaging. Sestamibi concentrates in cells with increased mitochondrial density, a common condition for metastatic breast disease.

PEM is a breast-specific version of a PET camera. Procedures are performed with fluorine-18 FDG, a sugar analog that is avidly metabolized as an energy source for cancer cells.

MBI, BSGI, and PEM are all designed as more diagnostically specific and less expensive alternatives to breast MRI, the current gold standard for diagnosing and evaluating difficult breast cases, especially women who have highly dense breasts or carry BRCA1/BRCA2



A 51-year-old patient diagnosed with triple-negative, stage II invasive ductal carcinoma measuring 3.5 cm at greatest extent. The image at left is MBI performed prior to beginning neoadjuvant chemotherapy. The middle MBI image was taken three weeks after initiation of chemotherapy (Taxol and carboplatin) and shows near-complete interval resolution of tracer uptake within the tumors, indicating good imaging response to chemotherapy. The MBI image at right was acquired after four months of chemotherapy and is negative, indicating complete response. At surgery, no residual disease was found.

mutations that make them genetically susceptible to early-onset breast and cervical cancer.

The American Cancer Society (ACS) recommends MRI and mammography screenings annually for women at high risk of breast cancer, classified as greater than a 20% lifetime risk. It advises women at moderately increased risk (15% to 20% lifetime risk) to discuss the potential value of MR screening with their doctors.

Though no definitive clinical trial has been published for any of the functional technologies, preliminary studies suggest they perform well for claustrophobic women who don't tolerate MRI, and for women who harbor metallic implants that are contraindicated for MRI.


---

## MBI casts wider net for improved breast cancer diagnosis

Advances in Molecular Breast Imaging • An AuntMinnie.com Special Report • Sponsored By: **GAMMAMEDICA, INC.**

Copyright © 2010 AuntMinnie.com

[www.gammamedica.com](http://www.gammamedica.com)



MBI proponents believe that it could first have a role in breast cancer screening for at-risk populations, and possibly later aid older women in the general population. The realization of that vision could lead MBI into the mainstream of breast imaging, a goal that neither BSGI nor PEM have yet realized. But MBI developers acknowledge they will have to reduce the radiation dose from MBI before it will be acceptable for screening use.

## A clinical evolution

Molecular breast imaging represents an evolution of work done on scintimammography starting in the 1990s, when investigators began performing Tc-99m sestamibi scans on general-purpose gamma cameras. But scintimammography never caught on with breast imaging practitioners, according to Michael O'Connor, PhD, a medical physicist at Mayo who has conducted early work on MBI.

The highest resolution possible during functional imaging occurs within a few millimeters of the scanner's collimator and detector, according to O'Connor. Optimizing resolution on a conventional gamma camera during scintimammography proved impossible because the patient had to be imaged in a prone position. The ability to detect small tumors was limited because the breasts were about 15 cm from the collimators and up to 25 cm from the region of interest.

The breasts could also only be visualized from the lateral side and anterior/posterior views. Side-by-side correlations with the craniocaudal and mediolateral oblique views acquired from mammography were difficult.

The new functional breast imaging scanners overcome these problems by reducing the size of the detector and integrating it into the breast compression device. The breast presses against the collimator/detector face while the patient is imaged in a seated position.

The use of matched, solid-state cadmium zinc telluride (CZT) detectors in a dual-head configuration helped O'Connor and colleagues at the Mayo Clinic to optimize detector geometry for their MBI system laterally through the breast, and it improved the typical 3- to 4-mm resolution expected from such a camera to 1.6 mm. Each square hole in the tungsten collimator is matched with a pixel in the detector and optimized for imaging objects within 3 cm of the collimator surface. Each CZT detector is positioned with an individual pixel element, O'Connor said.

MBI can detect lesions as small as 3 mm in diameter, according to O'Connor. Its sensitivity to tissue abnormalities with diameters of 5 mm to 20 mm is 90%.

"A key component in our design was optimizing our ability to detect tumors 5 mm to 10 mm because of the importance of lesions in that range of sizes for the patient's prognosis," he said.

The capabilities have been integrated into the LumaGem scanners commercialized by Gamma Medica. The firm secured U.S. Food and Drug Administration (FDA) 510(k) clearance to market the MBI configuration in December 2009, and commercial shipments began this summer.

In contrast, another functional breast imaging technology, the Dilon 6800 BSGI scanner from Dilon Diagnostics, uses a single detector head

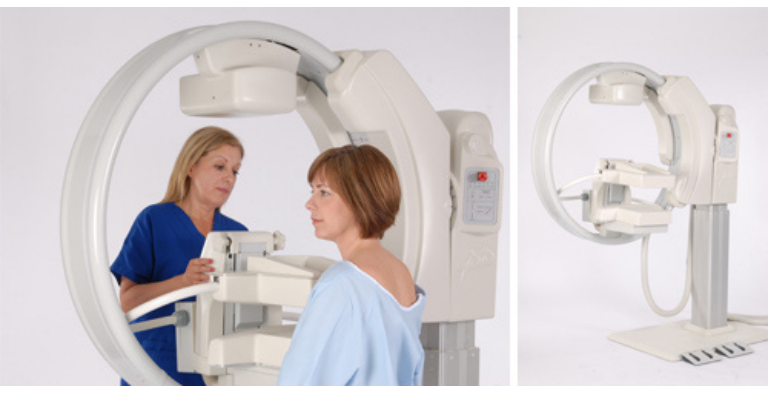---

## MBI casts wider net for improved breast cancer diagnosis

Advances in Molecular Breast Imaging • An AuntMinnie.com Special Report • Sponsored By: **GAMMAMEDICA, INC.**

Copyright © 2010 AuntMinnie.com

[www.gammamedica.com](http://www.gammamedica.com)



The LumaGem molecular breast imaging (MBI) camera is a dedicated breast imaging system with cadmium zinc telluride (CZT) digital detectors.

with pixelated sodium iodide scintillator technology, according to Doug Kieper, vice president of science and technology at the Newport News, VA, firm. An array of position-sensitive photomultiplier tubes (PMTs) gives the system the ability to localize an event within a single PMT to within 0.1 mm. Each PMT has the ability to identify the location of scintillation events without needing Anger logic, the localization method used in conventional gamma cameras.

San Diego-based Naviscan, the leading commercial developer of positron emission mammography, has incorporated many of the patient positioning and resolution features found on MBI and BSGI into its PEM scanner. Promoted as an alternative to breast MRI, PEM detects breast tumors as small as 2 mm in diameter.

## Clinical experience

BSGI is typically used for recently diagnosed cases in the same way MRI is used: to look for multifocal and multicentric disease after diagnostic mammography and ultrasound, but before biopsy, according to Lillian

Stern, MD, an assistant professor of radiology at Thomas Jefferson University and director of the Women's Health Center at Methodist Hospital in Philadelphia.

A small role has been carved out for BSGI since its installation at the breast imaging center four years ago. About five BSGI procedures are performed there every week to look for disease after diagnostic mammography and ultrasound when MRI can't be used. During long-term follow-up, it is performed to differentiate between malignant recurrence and scarring from previous surgery, she said.

BSGI also substitutes for MRI for monitoring the response to adjuvant chemotherapy before surgery. After a baseline scan, it is performed immediately after a three- and six-month regime of chemotherapy depending on the case and the preferences of the oncologist, she said. The lack of sestamibi uptake correlates with a positive response before mastectomy. High uptake correlates with progressive disease or a partial response. In those instances, the findings suggest that the oncologist should shift to a different chemotherapy after surgery, Stern said.

SNM of Reston, VA, announced in June guidelines covering seven diagnostic indications for BSGI. They include initial breast cancer staging; investigating suspected recurrence; indeterminate abnormalities, such as nipple discharges; imaging of dense or augmented breasts; and cases involving MRI contraindications.

The Mayo group is also gaining experience with MBI for monitoring treatment. Several trials are under way, including a pilot project examining the value of MBI performed before and after neoadjuvant chemotherapy administered before mastectomy.

---

## MBI casts wider net for improved breast cancer diagnosis

Advances in Molecular Breast Imaging • An AuntMinnie.com Special Report • Sponsored By: **GAMMAMEDICA, INC.**

Copyright © 2010 AuntMinnie.com

[www.gammamedica.com](http://www.gammamedica.com)

"Results were encouraging," Hruska said. "We showed, especially among dense-breasted women, that we could accurately predict response to therapy compared to mammography for the same role."

PEM plays many of the same roles where it has been applied, said Wendie Berg, MD, PhD, a breast imaging radiologist in Lutherville, MD.

Cohort studies examining women with known or suspected breast cancer suggest that PEM's performance is similar to MRI. Studies have shown that its specificity is slightly better than MRI, she said in an interview.

A 2006 trial by Berg, for example, established sensitivity and specificity rates for PEM at 90% and 86%, respectively. She was encouraged by the 88% positive predictive value for determining noninvasively whether a suspicious lesion was cancer.

## MBI and cancer screening

While MBI aims to develop into a substitute for breast MRI for evaluating known cancers, the Mayo group is looking to expand the technology's role to breast cancer screening for high-risk women, as witnessed by the research Hruska presented earlier this year in New York City.

The study, conducted by lead author Deborah Rhodes, MD, of the Mayo Clinic, involved 936 at-risk women and MBI performed with blinded interpretations. In preliminary results reported last year, Rhodes indicated that the sensitivity of mammography alone for these difficult-to-image patients was 27%, while the sensitivity of combined mammography and MBI was 91%.



"There were seven cases in our screening trial where we picked up a cancer with MBI that was not seen on mammography."

Carrie Hruska, PhD  
Mayo Clinic, Rochester, MN

Eleven participants were diagnosed with breast cancer. One cancer was only seen on mammography, and seven were detected only with MBI. Two appeared with both modalities. One was missed by both, to be detected a year later. A paper on the research has been accepted by *Radiology*, and Rhodes will also present the paper at the upcoming RSNA meeting in Chicago.

"The results suggest that MBI can detect more cancers than mammography in dense breasts," Hruska said.

## Questions on radiation exposure

But before MBI or any other functional breast imaging modality can be used in a screening role, issues regarding radiation dose will have to be addressed.

In a study released on August 24 ahead of print for the October 2010 edition of *Radiology*, R. Edward Hendrick, PhD, a clinical professor of radiology at the University of Colorado-Denver in Aurora, concluded that a single BSGI or PEM exam carries a lifetime risk of inducing fatal cancer that is greater than the risk from a lifetime of annual screening mammography starting at age 40.

---

## MBI casts wider net for improved breast cancer diagnosis

Advances in Molecular Breast Imaging • An AuntMinnie.com Special Report • Sponsored By: **GAMMAMEDICA, INC.**

Copyright © 2010 AuntMinnie.com

www.gammamedica.com

Hendrick, a medical physicist who advised the FDA on safety standards for the agency's mammography accreditation program, identified a huge difference in the effective radiation dose from mammography, which involves a dose of no more than 0.56 mSv, and the two functional breast imaging techniques. The BSGI and PEM procedures involve effective doses of 6.2 mSv and 9.4 mSv, respectively, he wrote. The average annual dose from natural background radiation is 3 mSv.

MBI was not included in his study, but Mayo's screening trial involved procedures that exposed subjects to 20 mCi of radioisotope, a quantity that O'Connor said translates into an effective dose of 6.5 mSv.

Andrew Karellas, PhD, a professor of radiology at the University of Massachusetts Medical School in Worcester, recognizes the potential value of MBI for screening high-risk women, but he believes that dealing with MBI's relatively high radiation dose compared to screening mammography will be challenging. To be workable, the administered dose of Tc-99m will have to be less than one-tenth of the activity reported in Mayo's studies, he noted in written comments to *AuntMinnie.com*.

"Maintaining an adequate signal-to-noise ratio with this lower administered dose will require careful reassessment of the hardware, particularly the design of the collimator and the acquisition time for attaining adequate photon statistics," he wrote.

O'Connor agrees that the radiation exposure from MBI must be reduced, but he argues that such reductions can be achieved without sacrificing imaging accuracy. In anticipation of the safety requirement for screening, his group has been working on radiation reduction schemes for two years.



“Our goal is a 2-mCi [screening] study, which would give a radiation dose about the same as tomosynthesis.”

Michael O'Connor, PhD  
Mayo Clinic, Rochester, MN

At the time of the Rhodes screening study, Mayo was performing MBI with a unit featuring CZT detectors fitted with standard collimators; therefore, researchers had to use a 20-mCi dose of sestamibi to get adequate count rates and image quality, Hruska said. This is simply too high a dose to administer year after year on a screening basis, she acknowledged.

Since then, with the realization of MBI's higher sensitivity in dense breasts compared to mammography, Mayo researchers have redesigned the collimator and made other improvements to support a 4-mCi study, "which would give an effective dose at a comparable level to digital screening mammography," Hruska said.

"Our goal is a 2-mCi study, which would give a radiation dose about the same as tomosynthesis," according to O'Connor.

The Mayo Clinic has started a second screening study to compare the new low-dose MBI protocol to screening digital mammography. Thanks to the new design, researchers are getting better image quality at 4-mCi doses compared to the original 20-mCi dose, Hruska said.

Dilon Diagnostics is also developing radiation reduction strategies for its BSGI system. For PEM, screening


---

## MBI casts wider net for improved breast cancer diagnosis

Advances in Molecular Breast Imaging • An AuntMinnie.com Special Report • Sponsored By: **GAMMAMEDICA, INC.**

Copyright © 2010 AuntMinnie.com

www.gammamedica.com



applications are not under consideration, according to Berg. She believes its exposure levels are acceptable for diagnostic applications because few patients will rarely receive more than a few procedures.

At Mayo, Hruska stresses that more clinical testing is also necessary to validate the positive scientific findings and satisfy anecdotal experiences that exemplify MBI's early use for breast cancer screening.

"There were seven cases in our screening trial where we picked up a cancer with MBI that was not seen on mammography," she noted. "I would say that was a benefit for those women."

By James Brice  
AuntMinnie.com contributing writer  
September 14, 2010

Copyright © 2010 AuntMinnie.com

---

## MBI casts wider net for improved breast cancer diagnosis

Advances in Molecular Breast Imaging • An AuntMinnie.com Special Report • Sponsored By: **GAMMAMEDICA, INC.**  
Copyright © 2010 AuntMinnie.com [www.gammamedica.com](http://www.gammamedica.com)



# MBI could help breast centers caught in economic squeeze

As breast imaging facilities consider new technologies as possible adjuncts to mammography, the weak economy is becoming a factor in their decision-making process. In the face of falling patient volumes and squeezed capital equipment budgets, could molecular breast imaging (MBI) offer an alternative that enables breast centers to do more with less?

MBI's potential as a mammography adjunct comes from its potential advantages compared to the two more established complementary technologies: breast MRI and ultrasound. MBI is cheaper and less complex than breast MRI, and it's less user-dependent than breast ultrasound. Ultimately, MBI proponents believe that it could provide more tailored and cost-effective imaging that will improve care for patients and the bottom line for breast centers.

But MBI's arrival in the market -- with the new generation of solid-state digital dual-detector MBI systems just starting to ship this year -- comes at a difficult time for breast imaging. Many states have cut funding for breast screening programs due to the economic crisis, while women who have private coverage are confused over the recent controversy regarding mammography screening guidelines.

On top of that, the current reimbursement environment is hardly welcoming, with both third-party payors and Medicare casting a skeptical eye toward new technologies.

But with additional clinical validation, MBI's cost advantage over other adjunctive breast imaging technologies could enable it to carve out a niche as a complementary tool in the diagnostic workup of women with suspicious breast lesions.

## The economy's impact

How badly has the Great Recession affected mammography screening rates in the U.S.? Exact numbers are hard to come by, but anecdotal evidence indicates that it could be as much as a double-digit percentage decline in screening rates -- and that's on top of a 2% annual decline in screening mammography volume between 2000 and 2008 that's been documented by market research firm IMV Medical Information Division of Des Plaines, IL.

A typical scenario occurs when a woman finds herself out of work and losing her health insurance -- and, thus, access to subsidized or free mammography screening -- according to Bonnie Rush, president of Breast Imaging Specialists in San Diego.

"The loss of insurance has had a big impact as women [are putting] their own needs behind those of their families," Rush said.

Kathy Schilling, MD, medical director of imaging and intervention at the Women's Center - Center for Breast

Care at Boca Raton Community Hospital in Boca Raton, FL, has seen a 13% drop in volume.

Concern regarding the effects of healthcare reform only adds to the uncertain environment. Shrinking resources make efficiency and appropriate technology decisions critical.

## An economic advantage?

Given the economic situation, does it make any sense for breast imaging practices to look at acquiring new technology, especially something as novel as MBI? Ironically, yes, according to some breast imaging experts.

“Physicians and patients want a more expedient and specific exam, and nuclear medicine finds changes on a molecular level even before the angiogenesis that can be seen on an MRI,” Rush said. “[It is] easy to interpret and the purchase price versus the reimbursement makes it doable.”

How does the purchase price of an MBI system compare to that of other complementary breast imaging modalities? MBI developer Gamma Medica of Northridge, CA, sells a single-detector version of its LumaGem scanner for \$295,000 to \$349,000 and a dual-detector version for about \$549,000. This compares to a list price of \$900,000 to \$1.3 million for a dedicated breast MRI system. MBI also has less onerous siting requirements than breast MRI, which can add as much as \$300,000 for installation costs to the final price tag.

Rush cautions, however, that incorporating MBI technology into a breast care practice means “bridging the gap between anatomic and molecular imaging,



“Physicians and patients want a more expedient and specific exam, and nuclear medicine finds changes on a molecular level even before the angiogenesis that can be seen on an MRI.”

Bonnie Rush  
Breast Imaging Specialists, San Diego

[requiring] coordination and training for the nuclear medicine technologists and the breast imagers if they take over the interpretations.”

Education and physician buy-in remain paramount. Investments in these areas can pay off with the development of a solid referral base and the dissemination of MBI information to patients as an option for equivocal screening studies. And MBI’s novelty can be viewed as an advantage for breast centers looking to stand apart from the crowd.

“It is a great time to begin marketing the technology to set the facility apart from the competition and, thus, gain market share,” Rush said.

## Getting savvy

So let’s assume you’ve decided to take the plunge into MBI. Obtaining the technology and getting reimbursement require savvy. Key tasks for any center that’s purchasing an MBI system include the following:

- Choosing the technology that offers additional benefits relative to mammography
- Finding innovative ways to raise capital equipment purchasing funds

---

## MBI could help breast centers caught in economic squeeze

Advances in Molecular Breast Imaging • An AuntMinnie.com Special Report • Sponsored By: **GAMMAMEDICA, INC.**

Copyright © 2010 AuntMinnie.com

www.gammamedica.com

- Educating third-party payors and radiology management companies about the advantages of molecular imaging

"[Providers] need to be aware of what reimbursement is [with significant payors in their areas]; how are things paid," said Barbara Ossias, principal of Reimbursement Revenue Solutions of Middletown, MD.

From providers to manufacturers, determining if a modality is covered before investing in the technology is a huge but often overlooked factor, according to Ossias. Expect to see more and more scrutiny going forward as MBI comes of age.

"When you come out with something new, it may not be that you're necessarily having trouble getting reimbursed; it is a situation where no one has ever been asked the question of covering you," Ossias said.

Fortunately, Medicare already reimburses for MBI, using CPT codes 78800 or 78801 for imaging and A9500 for the technetium-99m sestamibi radiopharmaceutical used in the procedure. The average reimbursement amounts (per scan) for MBI and other complementary breast imaging modalities are as follows:

- MBI -- \$450
- Breast MRI -- \$1,100
- Breast-specific gamma imaging (BSGI) -- \$450
- Positron emission mammography (PEM) -- \$1,100

But before you can get paid, you need to educate. Ensuring that all the players understand what a breast center wants to do is critical to reimbursement.

The current approach, Ossias explained, involves not just working with each payor to establish a positive medical coverage policy, but also working with your radiology benefits management (RBM) company to make sure it understands what you want to do.

"We go to the radiology benefits firm [with] a luminary, a physician who believes in the service, and we start the education process," Ossias said. "They're not going to precertify something if they don't know what it is, what the cost is, and why it's something that has a beneficial outcome for the patient."

The good news, according to Ossias, is if a new technology's images are equivalent or better than those from the currently used modality, and if it's a much less expensive procedure to perform, payors will factor that into the equation.

## The efficiency factor

Ironically, a breast center that adds more advanced procedures -- and, thus, more expensive equipment -- to its practice may actually have a better chance of escaping economic stagnation as it can offer a wider range of services and avoid referring patients out for more advanced procedures.

"You have to improve your efficiencies, and it becomes a lot easier for breast centers if they have some of the higher-end procedures, such as MRI, biopsy, or PET imaging," Schilling said. "It's difficult to have a mammo center where you just do mammography."

Schilling's center has improved its efficiency by doing same-day reads, in which patients' exams are interpreted at the same time they're being imaged. If patients

---

## MBI could help breast centers caught in economic squeeze

need additional biopsies or imaging, they are scheduled internally to avoid losing them to another facility.

Treating patients more as individuals; learning biopsy histories, familial risk, and breast density; and offering additional screening tools make for more comprehensive care.



“You have to improve your efficiencies, and it becomes a lot easier for breast centers if they have some of the higher-end procedures.”

Kathy Schilling, MD  
Women’s Center - Center for Breast  
Care at Boca Raton Community  
Hospital, Boca Raton, FL

Centers that have already adopted digital mammography are probably better candidates for an MBI system compared to facilities that are still performing analog imaging. Digital imaging increases throughput, which, in turn, feeds more patients into adjunctive diagnostic modalities such as MBI.

“If [you] do additional mammos, it increases the number of breast MR studies that you do down the road,” Ossias said. “As molecular breast imaging becomes more [commonplace], it will increase use of more of those [procedures], even more than basic ultrasound.”

## Making choices

The arrival of new technologies can mean difficult choices. That’s particularly true as MBI joins two other functional breast imaging modalities, BSGI and PEM, on the market, while other non-nuclear modalities,

such as automated whole-breast ultrasound and conebeam breast CT, loom on the horizon.

The key is to seek out technologies that compensate for the well-known limitations of the current gold standard for screening: mammography. Breast centers need to look for technologies that fill in the gaps and help improve performance.

“You don’t want to pick a tool that’s going to give you nothing that’s incremental,” Schilling said. “You don’t want a tool that is finding those same cancers [as mammography] because you’re not gaining anything.”

A breast center’s existing technology and expertise can also factor heavily into its choice of new technology. Without MRI expertise, a center could prefer molecular imaging. Or if a center has an MRI scanner but can’t afford the time on it, molecular imaging may be preferable.

Breast centers should examine their procedure volumes and the extent to which they’re using existing equipment, Schilling explained. Physician preferences can also play a role. Some clinicians would rather do a nuclear study than an MRI study, and that weighs into the decision more than some of the other issues, according to Schilling.

Whatever the technology, reimbursement remains a critical component.

“Most centers are not going to be adopting things that aren’t being reimbursed,” Schilling said. “When most centers have no capital, I don’t see why you would pick anything that is not going to add to your bottom line.”

---

## MBI could help breast centers caught in economic squeeze

Advances in Molecular Breast Imaging • An AuntMinnie.com Special Report • Sponsored By: **GAMMAMEDICA, INC.**

Copyright © 2010 AuntMinnie.com

www.gammamedica.com

As payors continue to view imaging technologies as overly utilized, the reimbursement problem will be ongoing. All the new technologies face the same scrutiny.

"Until we can prove that it's an added benefit, they're not going to be that thrilled to introduce new codes," Schilling said.

## Change

Despite economic pressures, the practice of breast imaging is changing. Although x-ray-based mammography has been the gold standard for screening for decades, that doesn't necessarily mean it will still be the gold standard decades from now.

In fact, some MBI proponents believe the technology could develop into a screening modality for a larger population of women, such as replacing breast MRI, which is far more costly.

"As the technology is better understood, [I see it] becoming more of a screening tool because it's not so costly," Ossias said. "I think we're going to be screening more for the general population as opposed to just [women at] high risk."

Much of the recent controversy over mammography screening guidelines comes from an attempt to apply a one-size-fits-all approach based on age to determining when women should be screened. A better approach would be based on finding women at the highest risk of disease and having them undergo more frequent screening compared to women at lower risk.

"[For] high-risk women, MRI works well," according to Jennifer Harvey, MD, head of the breast imaging



*"If we invest our time and energy now into figuring out who can benefit the most from the resources we have, we may come out ahead ... [and] stop doing tests that are not getting much bang for the buck."*

Jennifer Harvey, MD  
University of Virginia Health System,  
Charlottesville, VA

division at the University of Virginia Health System in Charlottesville. "I think another step we're going to be making over the next five to 10 years is figuring out that next rung of the ladder -- the women who are higher risk than average but not those ultrahigh-risk women."

MBI and other functional breast imaging technologies such as BSGI and PEM could play an increasing role in detecting cancers as early as possible in these women, especially those with dense breast tissue. However, the radiation dose involved in functional breast imaging remains a concern for screening. To that end, researchers at the Mayo Clinic in Rochester, MN, are developing technologies that could reduce MBI's radiation dose dramatically (see "Radiation dose in women's imaging: Are we scared yet?").

Another wild card is healthcare reform and the role it will play in women's imaging. On the positive side, reform could bring millions of uninsured women into the healthcare system, where they could receive relatively low-cost preventive care such as mammography screening that leads, in turn, to increased use of complementary modalities such as breast MRI, ultrasound, MBI, BSGI, and PEM.

---

## MBI could help breast centers caught in economic squeeze

Advances in Molecular Breast Imaging • An AuntMinnie.com Special Report • Sponsored By: **GAMMAMEDICA, INC.**

Copyright © 2010 AuntMinnie.com

www.gammamedica.com



On the negative side, the amount that the U.S. currently spends on healthcare is widely acknowledged to be unsustainable, especially given an aging population. Efforts to rein in spending could affect the dissemination and use of new technologies.

While some worry about what reform will bring, others see it as positive for women.

“I am concerned about being forced to ration [healthcare], including breast screening,” Harvey said. “But ... if we invest our time and energy now into figuring out who can benefit the most from the resources we have, we may come out ahead of this [and] stop doing tests that are not getting much bang for the buck.”

By Lin Muschlitz  
AuntMinnie.com contributing writer  
September 14, 2010

*Disclosure notice: AuntMinnie.com is owned by IMV, Ltd.*

Copyright © 2010 AuntMinnie.com

---

## MBI could help breast centers caught in economic squeeze



# Radiation dose in women's imaging: Are we scared yet?

Major reductions have been made in mammography radiation dose over the past 16 years, thanks to technological innovation and national quality standards such as the Mammography Quality Standards Act (MQSA). Despite this progress, many public health advocates -- as well as women of screening age -- are more worried about dose than ever.

To some extent, low-dose breast imaging modalities such as mammography have been hit with backscatter from the controversy over MDCT, which delivers a much higher radiation dose than mammography in relative terms. But recent clinical studies indicate that the radiation involved in some adjunctive breast imaging modalities -- such as positron emission mammography and breast-specific gamma imaging -- may have a bigger impact than previously thought.

To what extent should women and their healthcare providers worry about radiation dose? Are fears of radiation-induced cancers from breast imaging exams legitimate, or are they overblown? And what about alternative breast imaging technologies targeted at women who may be younger, have dense breast parenchyma, or have a higher risk for cancer?

## A low-dose modality

X-ray-based mammography has always been one of the lowest of the low-dose imaging modalities. Cognizant of the health effects of serial screening


exams taken annually or biennially (depending on the screening protocol), vendors and healthcare providers have worked hard to find new ways to reduce dose.

That said, even screening mammography produces radiation dose that in some rare cases can induce cancer. But numerous studies have found that the number of cancers detected by mammography offsets the much smaller number of radiation-induced tumors.

Things get more complicated when discussing some of the newer adjunctive imaging modalities that are arriving at many breast clinics. The topic got renewed attention in August 2010 with the publication of a new study indicating that two relatively new nuclear breast imaging modalities -- positron emission mammography (PEM) and breast-specific gamma imaging (BSGI) -- can involve radiation doses that produce up to 20 to 30 times the risk of radiation-induced fatal cancer than digital mammography in women age 40.

Scheduled to appear in the October issue of *Radiology*, the study rates the risks of digital breast tomosynthesis, conebeam CT, PEM, and BSGI. The bottom line: Radiopharmaceuticals injected in a single BSGI or PEM study have a far higher potential for inducing fatal radiation-induced cancer than x-ray-based mammography.

"I would certainly think two or three times before recommending BSGI or PEM to a patient," said the



study's author, medical physicist R. Edward Hendrick, PhD, from the University of Colorado-Denver in Aurora.

Specifically, the standard dose of 740 to 1,100 MBq of technetium-99m (Tc-99m) sestamibi injected for a single BSGI study results in an effective radiation dose of 8.9 to 9.4 mSv. This dose is low when measured at the breast (2 mGy), but it's higher in the organs that clear the radiotracer from the system: 40 to 55.5 mGy to the large intestine wall and 20 mGy each to the kidneys, bladder wall, and gallbladder wall.

Hendrick's study found that this administered dose is associated with a lifetime attributable risk (LAR) of 26 to 39 cases of radiation-induced fatal cancer in 100,000 women age 40 years at exposure.

*"I would certainly think two or three times before recommending BSGI or PEM to a patient."*

R. Edward Hendrick, PhD

University of Colorado-Denver, Aurora, CO

Meanwhile, PEM typically involves a standard dose of 370 MBq of FDG. This results in an estimated effective dose of 6.2 to 7.1 mSv, with the highest organ doses delivered to the bladder, uterus, and ovaries (59 mGy, 8 mGy, and 5 mGy, respectively). The lifetime attributable risk of fatal cancers at this level of exposure is 30 cases in 100,000 women age 40 years, or 23 times that of digital mammography in women age 40. This risk declines progressively with age, with 80-year-old women having half the risk of 40-year-olds for both BSGI and PEM studies.

In comparison, two-view digital mammography has a mean average glandular dose of 3.7 mGy, which is

associated with a lifetime attributable risk of fatal radiation-induced cancer of 1.3 to 1.7 cases per 100,000 women. Analog mammography produces a slightly higher dose and LAR than digital mammography.

The report quickly generated headlines around the world, but should it be interpreted as a slam against nuclear breast imaging?

"I don't mean it to be sensational. I do mean to clarify that not all breast imaging modalities are the same," Hendrick said in an interview with AuntMinnie.com. "I think it's important to get that message out there, given the confusion around these nuclear medicine studies. That's something that some breast imagers didn't appreciate: the organ dosages when you administer radioactive agents."

## Screening with low-dose MBI

Hendrick's analysis did not include molecular breast imaging (MBI), due to the modality's relative novelty compared to BSGI and PEM at the time the research was conducted. Unlike BSGI, which uses a dedicated breast gamma camera with a single detector head and analog sodium iodide scintillation crystals, the newest generation of MBI uses two semiconductor-based cadmium zinc telluride (CZT) digital detectors to capture more of the gamma rays emitted by the Tc-99m sestamibi tracer. It's based on technology developed at the Mayo Clinic in Rochester, MN, and licensed to Gamma Medica of Northridge, CA, which began selling the system in the U.S. this year.

The question of radiation dose is very much on the minds of researchers at Mayo, who are working on a pair of papers on the topic. The first is a study in which


---

## Radiation dose in women's imaging: Are we scared yet?

Advances in Molecular Breast Imaging • An AuntMinnie.com Special Report • Sponsored By: **GAMMAMEDICA, INC.**

Copyright © 2010 AuntMinnie.com

www.gammamedica.com



low-dose MBI was used to screen 2,500 women with dense breasts, while the second is a theoretical paper that calculates the number of radiation-induced cancers that might occur if that low-dose MBI protocol was used as part of a widespread screening program for women with dense breast tissue -- which would be the sweet spot for MBI as a screening tool, according to Michael O'Connor, PhD, a medical physicist at Mayo.

"The eventual goal is [that] we'd like to have an alternative to mammography for women with dense breasts," O'Connor said. "MRI is too expensive and ultrasound is time-consuming. We're thinking MBI would be an alternative. The question is: Would it work at 74- to 148-MBq doses?"

To develop the low-dose technique, the Mayo team replaced the MBI system's lead collimator with one made from tungsten, then matched each hole in the collimator to an individual pixel in the CZT detector. This yielded a nearly threefold improvement in sensitivity with no loss in spatial resolution.

Next, they shifted to a wider energy window (110-154 keV), which produced more photon counts and resulted in a 150% to 200% gain in sensitivity with minimal loss of contrast. The changes are possible due to the MBI system's use of CZT detectors rather than sodium iodide scintillation crystals, O'Connor said.

The current low-dose screening protocol requires a radiopharmaceutical dose of 148 MBq, compared with the current standard dose of 740 MBq for MBI. Ultimately, Mayo researchers hope to get the radiotracer dose as low as 74 MBq, O'Connor said; less than that is probably beyond the physical limitations of the current instrumentation.

The low-dose technique is being used in the screening study of 2,500 women with dense breasts to test its effectiveness. The paper is scheduled to be published in an upcoming issue of *Radiology*.

Next, the Mayo researchers turned to examining the risk-benefit ratio of MBI studies performed at such low levels of radiation in a screening population. Using similar radiation risk models as in the Hendrick study, they calculated the risk-benefit ratios of using MBI in various populations of women with dense breasts, as this is the most challenging group for mammography. Publication of this study is scheduled for an upcoming issue of *Medical Physics*.


First, the researchers based their model on a standard dose of 925 MBq of Tc-99m sestamibi, which produced a benefit-risk ratio of approximately 5:1 if it were administered annually from age 40 to 80 in women with dense breasts. This means that among a population of 100,000 dense-breasted women, standard-dose MBI could cause 453 cancer deaths but save 2,408 lives.

This benefit-risk ratio worsens among younger women with dense breasts, however. A woman with extremely dense breast tissue has five times the risk relative to a woman with fatty breast tissue. In dense-breasted women, therefore, performing annual 925-MBq MBI exams for women ages 40 to 49 produces a risk-benefit ratio of roughly 1:1 -- meaning that standard-dose MBI would cause as many deaths as it prevented in this hypothetical scenario.

That ratio improves markedly with Mayo's low-dose protocol, however. When the model is changed to use a Tc-99m dose of 111 MBq (halfway between the 74 to 148 MBq the Mayo team is targeting), the result is a

---

## Radiation dose in women's imaging: Are we scared yet?



ratio of roughly eight cancer deaths reduced for each one caused in a dense-breast population of women ages 40 to 49. The findings get even better when women of all ages are included: The low-dose protocol produces a benefit-risk ratio of 46:1 for women ages 40 to 80 with dense breasts.

## Breast CT and other options

While low-dose MBI undergoes research evaluation, there are explorations on other fronts. Digital breast tomosynthesis is still under development; Hendrick's review notes that radiation doses for this technique are one to two times the doses from two-view mammography.

Another option is dedicated breast CT, also not yet commercialized in the U.S., which will likely produce a radiation dose similar to or slightly higher than two-view mammography. As with mammography but unlike the nuclear medicine techniques, radiation is absorbed only in the breast tissue. Hendrick estimates that lifetime attributable risk for both digital breast tomosynthesis and dedicated breast CT would be one to two times those associated with two-view mammography.

Though MBI will not find smaller tumors due to inherent limitations ("At 4 mm you run into trouble based on the physics of the detectors," O'Connor said), MRI may be too sensitive, picking up benign processes or very small tumors that the body will reabsorb, according to Mayo researchers. It's also costly at more than \$1,100 per exam, compared with \$300 for a mammogram and an expected reimbursement of \$500 per MBI exam at the Mayo Clinic. This is comparable to the price for a BSGI scan.

What's more, the cost of the radiotracer used in MBI has plummeted since Tc-99m sestamibi went off patent about a year ago, dropping from \$150 a dose to \$25 for a vial, according to O'Connor. The MBI scanner costs roughly \$450,000.

There is another inexpensive, nonionizing option: ultrasound. However, a recent American College of Radiology Imaging Network (ACRIN) trial, ACRIN 6666, of whole-breast ultrasound and MRI in a population at high risk for breast cancer, did not make a resounding case for ultrasound as a screening method, according to O'Connor, due to false positives and cost-effectiveness questions regarding the length of the exam. Adding a single screening ultrasound to mammography yielded an additional 1.1 to 7.2 cancers found per 1,000 high-risk women, but it also substantially increased the number of false positives.

In other words, mitigating breast imaging radiation will be a concern well into the foreseeable future.

## Radiation reality check

When analyzing the potential effects of medical radiation dose, several factors need to be considered: First, humans are already exposed to radiation in their natural environment. Second, no one really knows for sure the true health impact of radiation at very low levels.

Both Hendrick and O'Connor place their dose analysis in the context of the average annual effective dose a person receives from background radiation in the natural environment: about 3 mSv. This natural radiation exposure varies by location -- ironically, Hendrick resides in Colorado, where both cosmic and terrestrial radiation are greater by a factor of 1.5 than elsewhere

---

## Radiation dose in women's imaging: Are we scared yet?

in the U.S., thanks to high altitude and uranium-enriched soils. Hendrick's paper notes that effective dose from BSGI and PEM studies equals approximately two to three years of natural background radiation exposure.

But one needs to also keep in mind the cumulative effect of natural background radiation, which begins hitting individuals the day they are born, according to O'Connor. If women received an MBI screening study at the higher 925-MBq dose every year between the ages of 40 and 80, the number of deaths caused by radiation from those exams would be half the number caused by natural background radiation, O'Connor said.

"The cumulative effect of background radiation over your life is far, far greater than any of these medical procedures," O'Connor said.

What's more, no long-term population-based studies have been conducted that track how many patients developed cancer from the relatively low levels of radiation produced by medical imaging studies. Instead, estimates such as lifetime attributable risk are based on the linear no-threshold theory, which starts with death rates found in cases of high levels of radiation exposure, such as the Chernobyl nuclear accident or the Japanese atomic bomb attacks, and extrapolates them to much lower exposure levels like those found in medical imaging.

## Understanding radiation exposure

Ultimately, medical physicists like O'Connor and Hendrick see increasing the awareness of patients and physicians about medical radiation as a never-ending responsibility. The challenge was chronicled in a July 2008 article in *Radiology* by Mettler and colleagues.



“The cumulative effect of background radiation over your life is far, far greater than any of these medical procedures.”

Michael O'Connor, PhD  
Mayo Clinic, Rochester, MN

"Most physicians have difficulty assessing the magnitude of exposure or potential risk," the authors wrote. "Effective dose provides an approximate indicator of potential detriment from ionizing radiation and should be used as one parameter in evaluating the appropriateness of examinations involving ionizing radiation" (*Radiology*, Vol. 248:1, pp. 254-263).

Hendrick observed that these difficulties exist at the highest levels: "Even the 2009 [U.S. Preventive Services Task Force] report on mammography and its benefits and harms misestimated the dose and, therefore, the risk from mammography. The major part of the decision wasn't based on the risk of radiation-induced cancers, but they overstate the risks and then they don't discuss them. They didn't do a complete job, let's put it that way, of estimating the risk," said Hendrick, who plans to submit a paper on the topic to the *American Journal of Roentgenology*.

"Absorbed dose is energy deposited per unit mass of tissue," he continued. "You don't add the dose to the first breast to the second breast. This is what a first-year radiology resident learns when they cover absorbed dose."


---

## Radiation dose in women's imaging: Are we scared yet?

Advances in Molecular Breast Imaging • An AuntMinnie.com Special Report • Sponsored By: **GAMMAMEDICA, INC.**

Copyright © 2010 AuntMinnie.com

www.gammamedica.com



As nuclear medicine and CT-based modalities gain traction in breast imaging, a new understanding of the needs of specific female populations based on age, breast density, disease, or genetic risk factors may accumulate. In its 2008 report on ionizing radiation, the United Nations Scientific Committee on the Effects of Atomic Radiation (UNSCEAR) named just two special populations affected by radiation: children and fetuses. Could future reports recognize women?

“In pediatric patients, the message has gotten across, particularly to radiologists, that you really have to work as hard as possible to lower the dose in exams,” Hendrick said. “They are less aware that the same dose to a female is greater than to a male, and that younger females have more risk. They have more radiosensitive organs than males, and, typically, for the same dose -- whether it’s internally or externally administered -- females are smaller,” Hendrick said.

O’Connor agrees that not enough attention has been paid to the effects of radiation on women’s reproductive organs. But he also believes that any discussion of the risks of medical radiation exposure should be placed against the backdrop of natural background radiation.

“If you were really concerned about radiation, no one should be allowed to live in the Rocky Mountains,” O’Connor said. “That would save more lives than all the medical radiation exposure.”

By Alexandra Weber Morales  
AuntMinnie.com contributing writer  
September 14, 2010

Copyright © 2010 AuntMinnie.com

---

## Radiation dose in women’s imaging: Are we scared yet?

advances in...


# MBI

MOLECULAR  
BREAST  
IMAGING

AN AUNTMINNIE.COM SPECIAL REPORT



SPONSORED BY: **GAMMAMEDICA**




LEFT TRANS 1:00 4CH

## New imaging tools address challenges of dense breast tissue

Nancy Cappello, PhD, was shocked when she received a diagnosis of breast cancer in February 2004. The Connecticut resident ate right, exercised, and had annual mammograms -- in fact, she'd received a negative mammogram just two months prior. But unbeknownst to Cappello, she was a member of an unlucky club of women -- those with dense breast tissue, in whom mammography has less than a 50% chance of catching breast cancer.

Some two-thirds of premenopausal women and one-quarter of those who are postmenopausal have dense breast tissue. In addition to confounding conventional x-ray-based mammography, women with dense breasts have also been found to have a higher risk of breast cancer.



“What amazes me is that I hear from radiologists and other physicians [every week] who ... are sold on informing women of their breast density.”

Nancy Capello, PhD  
Are You Dense

In Cappello's case, she underwent the full battery of treatment, including mastectomy, chemotherapy, radiation therapy, and breast reconstruction, and her cancer is currently in remission. She channeled her


frustration over her missed diagnosis into political activism, forming the awareness group Are You Dense and helping to pass a Connecticut law in October 2009 that requires physicians to inform patients of their breast density status.

Cappello's story highlights the need for more advanced imaging tools to penetrate the conundrum of dense breast tissue. While ultrasound and breast MRI have won some converts (in Cappello's case, ultrasound helped identify her tumor), other imaging researchers see potential in newer technologies just now arriving at breast care centers.

### A tarnished gold standard

Though mammography remains the gold standard for screening women in the general population, the modality faces limitations in women with dense breast tissue, according to Wendie Berg, MD, PhD, a breast imaging radiologist in Lutherville, MD.

“We know that dense breast tissue hides cancer: At least half of cancers present are not identified with mammography in women with dense breast tissue,” Berg said. These tumors are similar in density to surrounding tissue, resulting in decreased contrast and obscured visualization of lesions. What's more, there's no way to tell whether a woman has dense breast tissue until she's already been imaged with mammography.



The American College of Radiology (ACR) has developed a widely accepted BI-RADS classification system comprised of four breast density categories:

1. Almost entirely fat
2. Scattered fibroglandular density
3. Heterogeneously dense
4. Extremely dense

The latter categories are responsible for the majority of cancers that remain undetected. In fact, a study presented at the 2010 American Association for Cancer Research (AACR) meeting revealed that women with a breast density of at least 75% were four to five times more likely to develop breast cancer than women with little or no density.

Ultrasound has been proffered as a solution to the dense breast conundrum and, indeed, it does improve the performance of mammography in this population of women. For example, according to results from the American College of Radiology Imaging Network (ACRIN) 6666 trial reported in 2008, researchers found that mammography’s sensitivity in detecting those cancers was only 50%. However, when ultrasound was added to mammography, the researchers were able to increase sensitivity to 78%, suggesting ultrasound might be a useful supplemental tool in identifying breast cancer for this population.

But ultrasound isn’t necessarily an ideal solution: The technique is highly operator-dependent and requires a high level of expertise to perform. This has led some breast imaging specialists to seek out alternative modalities.



“We know that dense breast tissue hides cancer: At least half of cancers present are not identified with mammography in women with dense breast tissue.”

Wendie Berg, MD, PhD  
Lutherville, MD

## Alternative approaches

To begin with, digital mammography has been shown to be more effective for women with dense breast tissue, as well as for women who are peri- or premenopausal (generally women younger than 50), according to the ACRIN Digital Mammographic Imaging Screening Trial (DMIST) reported in 2005.

Besides digital mammography, ultrasound, MRI, positron emission mammography (PEM), and molecular breast imaging techniques are being used to meet the imaging challenges posed by dense breast tissue.

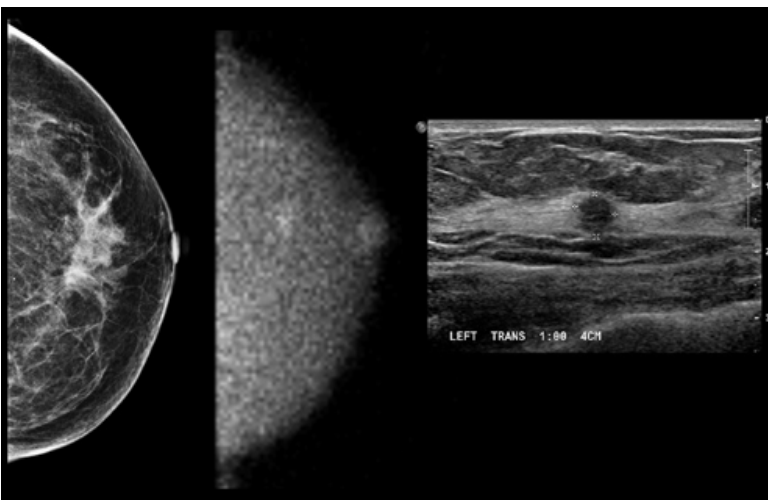

## Ultrasound

In current usage, ultrasound provides confirmation of suspicious areas and offers guidance for core needle biopsy procedures. Currently, ultrasound’s use as a screening modality is not supported.

Although ultrasound can increase absolute rates of cancer detection 30% above mammography alone, as mentioned, limiting factors of the technology include its operator-dependent nature, the expertise required to perform these time-consuming studies, a shortage of sonographers adequately trained to perform the

---

## New imaging tools address challenges of dense breast tissue



Images show (from left to right) mammogram (craniocaudal view -- read as negative), MBI study (craniocaudal view), and ultrasound study. Patient had an approximately 6-mm invasive cancer of the breast, which is seen on MBI and confirmed by ultrasound and pathology. Patient was a participant in a Mayo Clinic screening study comparing mammography and MBI in women with dense breast tissue. The study was performed using 148 MBq of technetium-99m sestamibi and a 10-minute view. Image courtesy of Michael O'Connor, PhD.

studies, and low reimbursement rates. Typical Medicare payments average \$85 to \$120, which is insufficient to fully cover the cost of a breast scan.

False positives generated with ultrasound are also a concern, according to Donna Plecha, MD, an assistant professor and director of breast imaging at University Hospitals of Cleveland. This results in an increased number of biopsies performed on benign lesions, leading to both increased expense and higher anxiety for patients.

## Breast MRI

This modality has been recommended for screening use in some high-risk women, and it provides further

definition of tumor mass and shape to inform surgical interventions. It is probably too costly to be used for mass screening, however, and like ultrasound it can lead to a large number of false positives that have to be followed up.

Breast MRI has other drawbacks, according to Berg. Gadolinium MRI contrast must be injected, and scans require approximately 30 minutes to complete. Some women are not candidates for MRI because they are claustrophobic or have metal implants, and there is a shortage of sonographers adequately trained to perform the studies.

## Nuclear breast imaging


Nuclear imaging of the breast is a generic term that covers many different forms of nuclear medicine scans, from PEM to breast-specific gamma imaging (BSGI) to molecular breast imaging (MBI). Both BSGI and MBI are based on a gamma camera and the technetium-99m (Tc-99m) sestamibi radiopharmaceutical, but MBI typically is performed with a dual-head camera. Also, BSGI employs sodium iodide scintillation crystals, while MBI makes use of cadmium zinc telluride (CZT) digital detectors.

With all these techniques, concern about the amount of radioactive tracer required often drives the decision as to how they are used: screening versus diagnostic workup and treatment management.

## PEM

Positron emission mammography is a breast-specific PET exam that uses FDG to provide additional information about tumor size and shape.

# New imaging tools address challenges of dense breast tissue



Plecha describes PEM as an FDG-based scan specifically designed for breast imaging, with smaller detectors than whole-body PET. Its primary application is for use in women who already have diagnosed breast cancer. PEM is not indicated for screening.

In research to appear in the December issue of *Radiology*, Berg reports on the results of a study of 388 women that compared PEM to MRI. The study found that PEM shows increased precision at identifying benign and cancerous lesions, which helped to reduce unnecessary biopsies. Another benefit PEM holds over MRI is that the scans are easier to interpret, with only 12 images of the breast viewed in two projections for a total of 24 images, compared with 1,000 to 2,000 images produced by a typical MRI.

Issues of radiation dose required for PEM are currently being addressed, with preliminary research suggesting that dose can be cut by as much as 70%, to 111 MBq of FDG, as reported at the American Association of Physicists in Medicine (AAPM) annual meeting in August 2010. Naviscan of San Diego has commercialized the PEM technology.

## BSGI

Breast-specific gamma imaging employs a gamma camera to detect uptake of Tc-99m sestamibi in women with suspicious areas in breast tissue. BSGI uses a single-head gamma camera to detect “hot spots” of abnormally increased metabolic activity found in breast cancer lesions. The original question posed about this technology was whether it was sensitive enough to replace other tools such as MRI or ultrasound, and initial studies suggest it meets necessary sensitivity thresholds.

Dilon Diagnostics of Newport News, VA, has commercialized the BSGI technology.

## MBI

Molecular breast imaging employs a gamma camera with one or two semiconductor-based CZT detectors to image the breast after the patient has been injected with Tc-99m sestamibi. The technology has been the focus of researchers at the Mayo Clinic in Rochester, MN.

The first indication for MBI is for the workup of women with suspicious breast lesions found on mammography. But Mayo Clinic researchers are also investigating the feasibility of using the system for screening purposes, primarily in women with dense breast tissue.

Gamma Medica of Northridge, CA, has licensed and commercialized the MBI technology developed at the Mayo Clinic.

## MBI's potential

Michael O'Connor, PhD, a professor of radiologic physics at the Mayo Clinic, was instrumental in developing the system. In an initial study of 1,000 women, the system detected three times as many cancers as mammography. The caveat was that the exams used a typical sestamibi dose of 740 MBq, which means the test would not be feasible as a screening technique on an annual or biennial basis. The researchers have since made enhancements to the MBI equipment to enable a reduction in dose to 74 to 148 MBq, resulting in a radiation dose comparable to mammography (see “Radiation dose in women’s imaging: Are we scared yet?”).


---

## New imaging tools address challenges of dense breast tissue

Advances in Molecular Breast Imaging • An AuntMinnie.com Special Report • Sponsored By: **GAMMAMEDICA, INC.**

Copyright © 2010 AuntMinnie.com

[www.gammamedica.com](http://www.gammamedica.com)



“You would not look at [MBI] to replace mammography for women who do not have dense breasts, because for them mammography does very well.”

Michael O'Connor, PhD  
Mayo Clinic, Rochester, MN

“Right now it’s used as a secondary diagnostic tool, but if you are looking at a screening procedure every year or two for 40 years of a woman’s life, you must optimize the dose,” O’Connor explained. “You would not look at this technology to replace mammography for women who do not have dense breasts, because for them mammography does very well.”

Another concern the team has worked to address involves workflow challenges. Enhancements to the system are designed to reduce scanning time from 40 minutes to 25. O’Connor noted that the scans are quick to read because they have only four to eight images.

A comparison of MBI to MRI reveals the cost differential between the technologies, with a typical MRI scan costing \$1,100, while MBI is projected to be billed in the \$400 to \$500 range.

### What does the future hold for MBI?

The Mayo Clinic team is exploring the development of a system that combines MBI with an anatomical modality such as ultrasound to enable biopsy while the patient remains in the same position. “We’d like to be able to have the radiologist perform the biopsy with ultrasound guidance while the woman is in the MBI machine,” O’Connor said.

Plecha suggested that a system of tailored screening practices that analyzes factors such as breast density, family history, and lifetime risk of breast cancer may provide guidance as to the effective use of all breast imaging techniques. Individual circumstances would inform which imaging technique was most appropriate for a particular patient.

Even with the workflow issues produced by longer scan times of molecular imaging, not all patients would need those exams, so the effect on overall department workflow could be manageable, Plecha noted. She suggested using mammography technologists to position women for the MBI exam, because they possess expertise in this area.

As the imaging community searches for better tools to deal with dense breast tissue, efforts to raise awareness of the problem among women continue. Cappello of Are You Dense has continued her advocacy campaign, and her group is now working with women outside Connecticut, forming a network called the Density Education National Survivors’ Effort (DENSE), to lobby for the passage of legislation like the Connecticut law in other states. Bills are being prepared for introduction in at least five states, as well as at the federal level.

“What amazes me is that I hear from radiologists and other physicians [every week] who want to do what we are doing in Connecticut, and are sold on informing women of their breast density,” Cappello said.

By Cheryl Hall Harris  
AuntMinnie.com contributing writer  
September 14, 2010

Copyright © 2010 AuntMinnie.com

---

## New imaging tools address challenges of dense breast tissue

Advances in Molecular Breast Imaging • An AuntMinnie.com Special Report • Sponsored By: **GAMMAMEDICA, INC.**

Copyright © 2010 AuntMinnie.com

www.gammamedica.com



# When to use advanced breast imaging: A tale of two centers

Few diagnoses strike more terror in the hearts of women than that of breast cancer.

Given the high-profile nature of this disease, there's little question about the rationale behind dedicated breast centers, which combine state-of-the-art imaging with direct diagnosis and treatment activities performed by highly specialized breast clinicians.

Advanced breast imaging modalities can provide specific clinical information designed to improve the detection and treatment of breast cancer, from the anatomic clarity of MRI to the functional activity revealed through nuclear breast imaging. Each modality has a unique role to play in managing patients with breast cancer.

But the proliferation of new technology can create challenges for today's breast care specialists, who must understand the relative strengths and weaknesses of each imaging approach and decide which patients should get what modality. Two comprehensive breast centers share their experiences in integrating and managing some of the most advanced technologies available for breast imaging and diagnosis.

## Imaging and dense breast tissue

Mammography is the screening modality of choice for women who meet the BI-RADS classification of fatty breast tissue or scattered fibroglandular density. More

than 40% of the millions of women undergoing mammography have dense breasts; for these women, another technique must be used.

Ultrasound is the initial tool of choice for targeted use to refine diagnosis of a mass detected on mammography, or for specific clinical indications such as pain or a lump detected by physical examination, according to Robin Shermis, MD, medical director of the Toledo Hospital Breast Care Center in Ohio. He considers the use of ultrasound for first-line screening to be problematic because the modality's specificity in detecting cancerous lesions is less than ideal.

MRI is useful for diagnostic work and preoperative staging, as well as in instances when a woman has a complex, dense mammogram that is difficult to determine the nature of the images or has equivocal findings that are hard to biopsy, Shermis explained. For women who meet the genetic criteria or have other personal risk factors, such as family history, that place them above a 20% risk of developing breast cancer, the center performs MRI scans as a form of tailored breast imaging. "I tell my patients with dense breasts that nothing can hide from an MRI," Shermis said.

Some centers have employed positron emission mammography (PEM) to further characterize lesions, monitor treatment response, or look for local recurrences or metastases. Essentially a breast-specific PET

scan that employs FDG as the radiotracer, the technique is not usually used for first-line imaging, but it offers greater specificity than MRI and reduces false-positive results.

Two other nuclear breast imaging modalities, both of which use the technetium-99m (Tc-99m) sestamibi radiopharmaceutical, are breast-specific gamma imaging (BSGI) and molecular breast imaging (MBI) (see "MBI casts wider net for improved breast cancer diagnosis").

How are the new technologies likely to be used in clinical practice, and to which patients should they be directed? A look at two cutting-edge breast care facilities can provide some answers.

## Anatomy of a new comprehensive breast center

Baptist Health of Northeast Florida in Jacksonville will open its Margaret and Robert Hill Breast Center in October 2010. The 24,000-sq-ft outpatient imaging center will serve as the cornerstone for Baptist Health's comprehensive approach to women with breast cancer in the community, and it's been designed to provide all necessary services for breast cancer management under one roof, according to Christine Granfield, MD, medical director of breast services at Baptist Health and a partner in the radiology practice Mori, Bean & Brooks of Jacksonville.

The center was designed to feature services and patient amenities to help reduce the stress of breast cancer diagnosis. This holistic approach to care will include massage therapists, yoga classes, and a special room to provide entertainment for children while their mothers receive treatment. Instead of a



Providing reading services for the new Margaret and Robert Hill Breast Center will be radiologists with the radiology practice Mori, Bean & Brooks: Back row, left to right: Sudha Bogineni-Misra, MD; Barbara Sharp, MD; Christine Granfield, MD; Jamie Surratt, MD. Front row: Mary Alderman, MD; Dianne Johnson, MD; Kathryn Pearson, MD. Not pictured: Trishna Patel, MD.

television blaring in the corner, the center will include a soothing architectural water feature.

In addition to providing diagnostic imaging, the center will have an adjoining floor dedicated to breast surgery, with radiation therapy and oncologic treatment available at the adjoining cancer center, Granfield said.

Currently, Baptist Health of Northeast Florida performs more than 60,000 exams a year throughout its system. Half of the exams are performed at its current 7,000-sq-ft center, which will be replaced by the new facility, and the remainder of the screening tests are performed at three outlying sister hospitals.

The new Hill Breast Center will feature an entire floor devoted to screening and also a diagnostic floor with five Senographe full-field digital mammography

## When to use advanced breast imaging: A tale of two centers

Advances in Molecular Breast Imaging • An AuntMinnie.com Special Report • Sponsored By: **GAMMAMEDICA, INC.**

Copyright © 2010 AuntMinnie.com

[www.gammamedica.com](http://www.gammamedica.com)

(FFDM) systems from GE Healthcare of Chalfont St. Giles, U.K.; six GE Logiq E9 ultrasound units; two stereotactic biopsy units; a LumaGem MBI system from Gamma Medica of Northridge, CA; and a dedicated GE Discovery MR450 MRI system with a breast biopsy table from Sentinelle Medical of Toronto in the basement.

Hill Breast Center is installing the MBI unit to help the facility deal with the diagnostic workup of a specific segment of the population: women with dense breasts who are at higher risk of breast cancer, but who would not be directed to breast MRI because they don't meet the American Cancer Society's (ACS) criteria of a greater than 20% to 25% lifetime risk of breast cancer to qualify for the modality.

Baptist Health has had experience with a PEM camera, but Granfield sees advantages to MBI that are prompting the facility to switch. The cost of an MBI system is about one-third that of a PEM unit; while reimbursement for MBI is lower (\$1,100 for PEM versus approximately \$450 for MBI), the price of the Tc-99m sestamibi radiopharmaceutical used by MBI is less than that of FDG used in PEM.

MBI also has workflow advantages. Unlike PEM, patients don't have to fast, Granfield said. She also believes that PEM reads are more complicated than MBI scans, in which radiologists basically only have to look for "hot spots" on images.

"That's important these days because you're trying to get through screening studies," Granfield said. "You want to be able to help those patients."

Granfield and colleagues will use the MBI system for diagnostic use and for screening patients with dense breasts and a family history of breast cancer, but who have less than a 20% lifetime risk of breast cancer, making them unsuitable for screening MRI per ACS guidelines. Also promising is work being conducted at the Mayo Clinic in Rochester, MN, on reducing the radiation dose of MBI (see "Radiation in women's imaging: Are we scared yet?").

## Equipment + expert staff = total approach

Radiologists at another advanced breast care center, at Toledo Hospital, believe it's impossible to overstate the importance of having well-educated and specialized technologists to perform imaging studies on the best equipment available, according to Shermis.

He considers digital mammography to be the centerpiece of Toledo's screening program, but ultrasound, MR, and MBI offer comprehensive imaging options. It's key that each member of the staff understands the best uses for each modality, he said.



*"You have to hope that if you spend more on detection and diagnosis, you'll end up spending less on treatment because hopefully you'll find lesions that are smaller."*

Robin Shermis, MD  
Toledo Hospital Breast Care Center

---

## When to use advanced breast imaging: A tale of two centers

Advances in Molecular Breast Imaging • An AuntMinnie.com Special Report • Sponsored By: **GAMMAMEDICA, INC.**

Copyright © 2010 AuntMinnie.com

[www.gammamedica.com](http://www.gammamedica.com)

Shermis described the imaging path for a typical woman who qualifies for an MRI, such as an individual with dense breast tissue who has a lifetime risk of at least 20% for developing breast cancer due to family history and/or personal risk factors. If a breast MRI indicates a suspicious area, the radiologist discusses the results with the patient, and he or she orders an ultrasound followed by ultrasound-guided biopsy of the suspicious area.

However, MRI is expensive and unavailable for women who don't qualify on the basis of risk. To address those needs, Toledo Hospital is acquiring the LumaGem MBI scanner in a dual-head configuration.

MRI is more expensive to perform than MBI, given the purchase price and costs of site preparation, installation, and maintenance, Shermis continued. Not only does the molecular exam require fewer resources, it also provides specificity in identifying cancerous tissue. If a patient has an equivocal mammogram, MRI shows many nondefined small areas, and if the lesion is not amenable to ultrasound, the molecular study can be used to determine whether the lesion is malignant.

Having multiple advanced imaging modalities available in-house means all follow-up studies are completed in one visit, which reduces opportunities for unnecessary delays in completing diagnosis and developing a treatment plan, Shermis explained.

The bottom line for all of the imaging is the necessity of integrating all modalities, with both dedicated technologists and specialized radiologists performing and interpreting the studies.

Reimbursement for some of the newer technologies such as MBI requires expert and diligent precertification activities, as well as many conversations with the medical directors of insurance plans, Shermis cautioned (see "MBI could help breast centers caught in economic squeeze").

## Economic realities produce challenges

The ideal management of women with breast cancer involves the integrated, comprehensive approaches described above, but the costs associated with care may ultimately determine which patients have access to the different advanced breast imaging techniques that are available.

While Medicare administrators and third-party payors are closely watching the costs incurred in the use of advanced imaging technologies, Shermis believes that when used wisely they can be cost-effective. He concluded with a reminder that when dealing with the overall expense associated with breast cancer, detection and diagnosis only accounts for 6% of the costs; the remainder is required for treatment.

"You have to hope that if you spend more on detection and diagnosis, you'll end up spending less on treatment because hopefully you'll find lesions that are smaller," Shermis said. "This will improve outcomes as well as reduce costs."

By Cheryl Hall Harris  
AuntMinnie.com contributing writer  
September 14, 2010

Copyright © 2010 AuntMinnie.com

---

## When to use advanced breast imaging: A tale of two centers